

DIROFILARIA HOLIDAYS IN FACE

Midhuna Prathap*, Amal John

Kerala ENT Research Foundation, Kollam, India

Abstract

Dirofilaria infections constitute an uncommon clinical entity in humans. The most common *Dirofilaria* species affecting the humans include *D. repens* and *D. immitis*. There are about 40 other species of *Dirofilaria* known to cause diseases in humans. The incidence of these infections have been on a rise with more cases being reported from different parts of the world each year. More than 1000 cases have been cited in literature now in diverse geographical locations and is still rising. European countries surrounding the Mediterranean region have been noted to be amongst the most affected areas.

Keywords:

dirofilariasis, zoonotic infection, nematode.

The key to diagnosis is differentiating it from other pathologies with similar presentations like malignant neoplasms, sebaceous cysts, fungal infections and abscesses.

This article reports a case series of the clinical presentation, characteristics and treatment of human dirofilariasis over the past 2 years at our institute.

Introduction

Dirofilariasis is caused by a nematode which belongs to the genus *Dirofilaria* and family Onchocercidae. (1) They can infect humans accidentally via vectors and have therefore been implicated in zoonotic infections worldwide.

Climatic changes and an increase in the movement of the parasite's reservoir have caused an increase in the geographic range of *Dirofilaria* from the traditionally endemic/hyperendemic southern regions thus increasing the risk of human infection. In addition, current summer temperatures are sufficient to facilitate extrinsic incubation of *Dirofilaria* in many areas of Europe. (2)

The aim of this paper is to present our experience in managing dirofilariasis at our institute.

Materials and Methods

The present study was conducted in our hospital where 3 patients with dirofilariasis were treated over the past 1 year

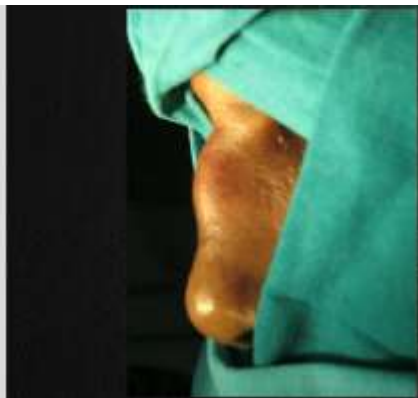


Fig 1. Swelling over nasal bridge

These cases were diagnosed with standard investigations and treated by surgical excision.

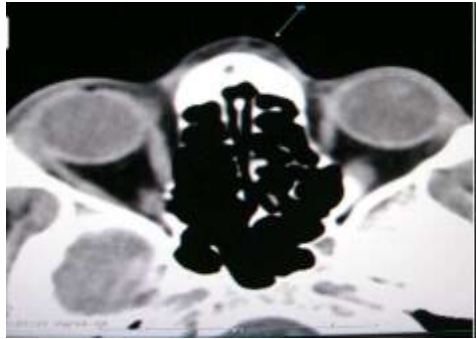

Fig 2. Swelling with encysted larva on ct pns

Local anesthesia was used at the site. Incision made over the swelling and blunt dissection done to identify the mass

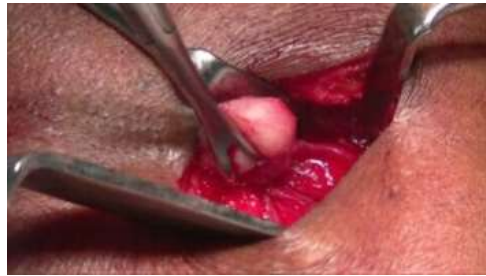

Fig 3. Encysted mass on dissection .

The cyst was cut open which revealed the larva.

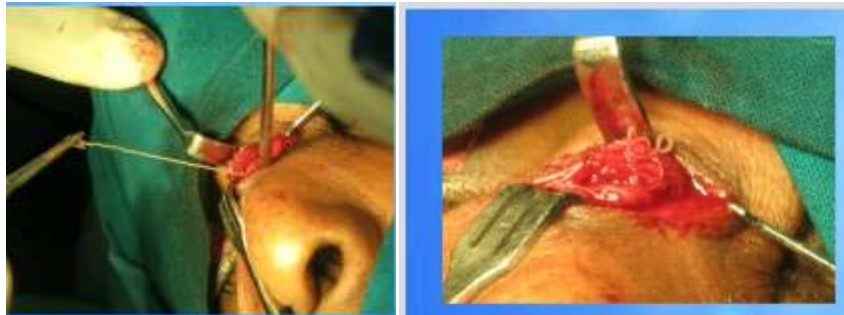

Fig 4 .Mass mass with larva

Mass removed in toto from the surface of the underlying muscle.

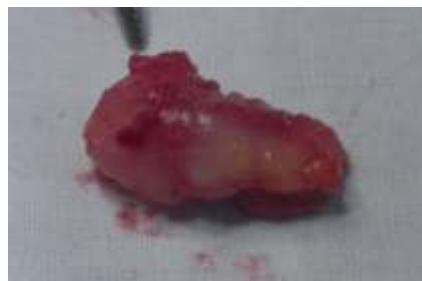

Fig 5. Cyst in toto

Regular small sized suction drain was inserted and wound closed with 3,0 prolene .

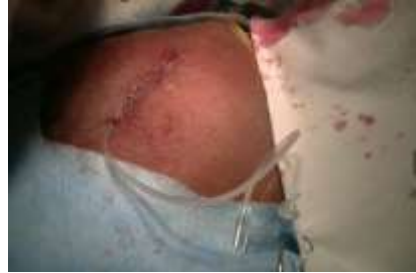

Fig 6.Suction drain and wound closure

Biopsy of the entire cyst with larva was sent for.

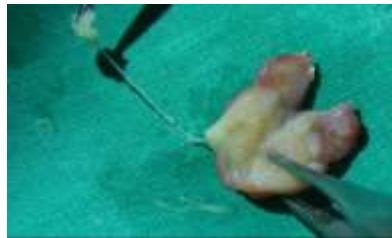


Fig 7.Cyst cut open with larva

Post operatively antibiotics , anti-inflammatory agents and analgesics were given.Drain removal was done after 24 hours and suture removal after 1 week

Discussion

The first case of human dirofilariasis documented dates back to the report of Addario in 1885 from Italy.(3)Cases of human dirofilariasis caused by *Dirofilaria repens* have been reported in Asia, Europe and Africa. *D. immitis* is also noted as a causative agent of dirofilariasis in India. First human case of pulmonary dirofilariasis in India, caused by *D. immitis*, was detected at autopsy and isolated from a child manifesting as portal cavernoma with pulmonary dirofilariasis. The most commonly reported manifestation of human dirofilariasis worldwide is subcutaneous or ocular disease caused by *D repens*.(4)

The incidence of ocular dirofilariasis is on the rise in several parts of India, particularly in Kerala.

Man is a dead end host for the parasite. In most cases of human infections ,a single parasitic lesion is found .The most frequent presentation of this parasitic lesion is in the head and neck region(64.6%) (5)

Travel history is an important aspect that should not be overlooked during history taking.Pathological identification by diagnostic evaluation of microscopic cross sections and identification of the dirofilarial worms by the presence of thick laminated cuticle broad lateral chords and large muscle cells is gold standard.(6)PCR (polymerase chain reaction) protocols may further aid identification in cases of poor specimen preservation techniques.Excisional biopsy is curative(7).There is a disagreement regarding administration of therapy after surgical excision and identification of a parasite. Some authors deny the necessity of specific therapy while other authors recommend it.(8)

Conclusion

Dilofilariasis represents a diagnostic problem since it produces symptoms which may be confused with other possibilities and thus this parasitic infection remains underdiagnosed. With changes in lifestyle of people and the rise in frequent travelling,a significant increase in this helminthic infection can be anticipated.To add to this is the current climatic variations which favours the survival of these zoonotic parasite may be contributory.

The early identification of the infection standard diagnosis and meticulous surgical technique provides satisfactory resolution of symptoms with a good clinical outcome. Increased awareness among clinicians may help in early identification and patient care.

Source of support: Nil

Conflict of Interest: None declared

References

1. Tilakaratne WM, Pitakotuwa TN. Intra-oral *Dirofilaria repens* infection: Report of seven cases. J Oral Pathol Med 2003;32:502-5.
2. Dzamic AM, Colovic IV, Arsic-Arsenijevic VS, Stepanovic S, Boricic I, Dzamic Z, et al. Human *Dirofilaria repens* infection in Serbia. J Helminthol. 2009;83(2):129-37.
3. Genchia C, Mortarino M, Rinaldi L, Cringoli G, Traldi G, Genchia M. Changing climate and changing vector-borne disease distribution: the example of *Dirofilaria* in Europe. Veterinary Parasitology. 2011;176:295-9
4. Vakalis N, Spanakos G, Patsoula E, Vam-Vamvakopoulos NC. Improved detection of *Dirofilaria repens* DNA by direct polymerase chain reaction. Parasitol Int. 1999;48:145-50
5. Wayne M, Meyers Ronald C. Helminthiasis. Washington, DC: Forces Institute of Pathology American Registry of Pathology; 2000. Neafie, Aileen, Marty, Douglas J. Wear. Pathology of Infectious Diseases
6. Collins BM, Jones AC, Jimenez F. *Dirofilaria tenuis* infection of the oral mucosa and cheek. J Oral Maxillofac Surg 1993;51:1037-40.
7. To EW, Tsang WM, Chan KF. Human dirofilariasis of the buccal mucosa: A case report. Int J Oral Maxillofac Surg 2003;32:104-6.
8. Glickman, L.T Grieve, R.B. & Schntz, P.M. - Serologic diagnosis of zoonotic pulmonary dirofilariasis. Amer. J. Med., 80: 161-164, 1986